



## PATIENT

Harleigh Grissom

## PRESENTING CLINICAL SIGNS

History: Chronic UTIs. Does not ever void voluntarily, but when she is excited or petted she voids. Owner thinks that she doesn't seem to know that she needs to void.

## SPECIES

Canine

Abnormal PE/Chem/CBC/UA Results: Normal PE. UA consistent with UTI. Urine culture pending. Plain radiographs suggest pelvic bladder.

## BREED

Bernadoodle

## ULTRASONOGRAPHIC EXAMINATION OF THE ABDOMEN

### Urinary System

The urinary bladder is suspected to be pelvically located based on the sonographic images. The bladder is moderately distended with normal wall thickness and a smooth mucosal surface. Luminal contents are anechoic. No cystic calculi are observed. The region of the trigone appears normal.

## SEX

Spayed Female

The left kidney presented normal size (6.84 cm in length); normal shape and architecture with smooth peripheral margins. There is a normal 1:3 cortex to medulla ratio with normal corticomedullary distinction. There is no evidence of pyelectasia, nephroliths, infarcts or hydroureter. Renal vasculature is normal.

## AGE

15 mos

The right kidney is normal size (6.69 cm in length); normal shape and architecture with smooth peripheral margins. There is a normal 1:3 cortex to medulla ratio with normal corticomedullary distinction. There is no evidence of pyelectasia, nephroliths, infarcts or hydroureter. Renal vasculature is normal.

## WEIGHT

50.5 lbs

### Adrenal Glands

The left adrenal gland is normal size (0.45 cm at cranial pole) (0.69 cm at caudal pole) (2.08 cm in length); normal shape; homogenous parenchyma. The glandular echogenicity and detail are unremarkable. Capsule, cortex, and medullary definition are normal. The phrenicoabdominal vein and surrounding vasculature are normal.

## INTERPRETED BY

Andrea Nicastro,  
DVM, Diplomate  
ACVIM (Small  
Animal Internal  
Medicine)

The right adrenal gland is normal size (1.27 cm at cranial pole) (0.52 cm at caudal pole) (2.55 cm in length); normal shape; homogenous parenchyma. The glandular echogenicity and detail are unremarkable. Capsule, cortex, and medullary definition are normal. The phrenicoabdominal vein and surrounding vasculature are normal.

## IMAGING PERFORMED BY

Harold Mike Beard

### Spleen

The spleen is normal in size (1.02 cm in width at the level of the hilus) with a normal capsular contour. There is appropriate echogenicity and echotexture. No focal lesions are observed. Splenic vasculature is normal.

## HOSPITAL NAME

West Prince AH

### Liver

The liver is subjectively normal in size with normal contours and structure. There is appropriate echogenicity and echotexture. No overt structural evidence of inflammatory, infiltrative or regenerative pathology is evident. Vascular and biliary tracts are of normal volume with no evidence of congestion. No pathological hepatic lymphadenopathy observed.

## REFERRING VET

Harold Mike Beard

The gall bladder lumen is moderately distended. The wall is thin and smooth. Luminal contents are anechoic. The cystic and common bile ducts are normal.

## INVOICE

10894

### Gastrointestinal

The gastric lumen is distended with ingesta and kibble. The gastric wall is normal in thickness with a normal layering pattern. The small intestinal lumen is segmentally dilated with chyme. The small intestinal wall

## DATE

5/12/22

thickness is normal with a normal layering pattern and appropriate mural detail. Discreet masses are not identified. The colonic wall is normal. No obstructive or overt infiltrative disease is noted.

#### ***Pancreas***

A portion of the pancreas is obscured by the gastric distention. In the visualized portion, no obvious pathology is observed.

#### ***Free Abdomen***

The peritoneal cavity is normal. There is no evidence of inflammation or effusion. A few mesenteric lymph nodes are visualized, the largest measuring 1.56 cm in length. The nodes are normal in shape and echogenicity.

### **ULTRASONOGRAPHIC FINDINGS**

#### **Primary Findings**

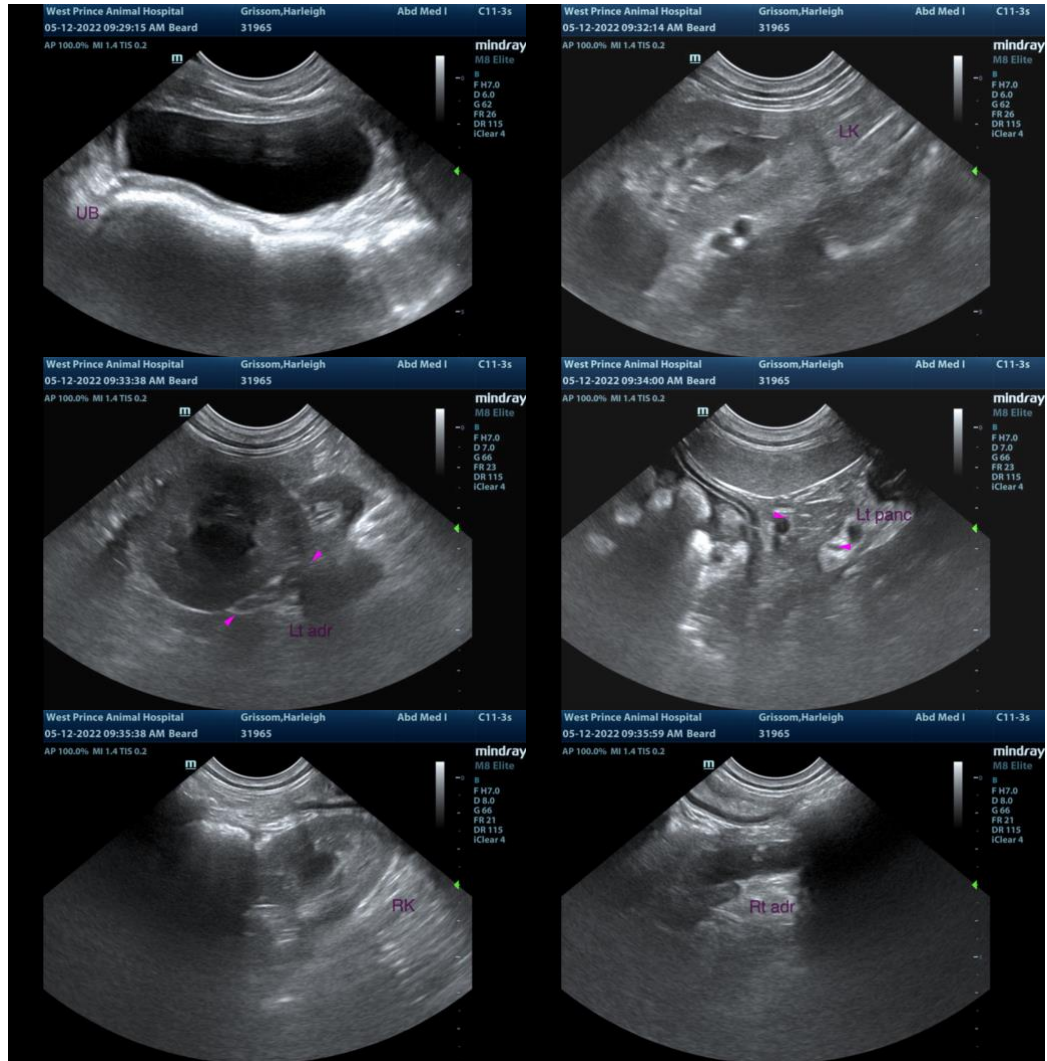
- Unremarkable abdomen. An obvious structural cause for the patient's chronic urinary tract infections is not identified in this study.

### **INTERPRETATION OF THE FINDINGS & FURTHER RECOMMENDATIONS**

A prolonged antibiotic course (i.e., 3-4 weeks) may be warranted and should be based on urine culture and sensitivity results. A repeat urine culture and sensitivity is recommended 5-7 days after the last dose.

Thorough examination of the external genitalia is recommended to assess for predisposing factors.

Baseline lab work, including a CBC Chemistry panel and T4 is recommended, if not already performed.



The information and recommendations provided are based on the images presented by the referring veterinarian/sonographer. No evaluation can be communicated regarding pathology that was not visible in the image/video clips provided.

Thank you for this referral. If the clinical or image interpretation does not parallel your findings or if I can be of any further assistance, please contact me.

**Andrea Nicastro, DVM, Diplomate DACVIM (Small Animal Internal Medicine)**  
[info@SonoPath.com](mailto:info@SonoPath.com)